

CLINICAL STUDY

Inferior petrosal sinus sampling in the differential diagnosis of Cushing's syndrome: results of an Italian multicenter study

Annamaria Colao, Antongiulio Faggiano, Rosario Pivonello, Francesca Pecori Giraldi¹, Francesco Cavagnini¹, Gaetano Lombardi and the Study Group of the Italian Endocrinology Society on the Pathophysiology of the Hypothalamic–Pituitary–Adrenal Axis

Department of Molecular and Clinical Endocrinology and Oncology, University of Naples 'Federico II', Italy and ¹Chair of Endocrinology, University of Milan, Italy

(Correspondence should be addressed to A Colao, Department of Molecular and Clinical Endocrinology and Oncology, University of Naples 'Federico II', Via Sergio Pansini 5, 80131 Naples, Italy; Email: colao@unina.it)

Abstract

Objective: To evaluate the diagnostic accuracy of inferior petrosal sinus sampling (IPSS) in the differential diagnosis of ACTH-dependent Cushing's syndrome as compared with pituitary imaging techniques.

Design and Methods: We retrospectively studied the diagnostic accuracy of basal and post corticotropin-releasing hormone (CRH) IPSS, magnetic resonance imaging and computed tomography in distinguishing pituitary from ectopic ACTH secretion in 97 Cushing's syndrome patients: 74 with Cushing's disease (CD) and 10 with ectopic ACTH secretion (EAS). Thirteen patients were excluded because of unconfirmed diagnosis. The difference between IPSS and pituitary imaging techniques in the correctly localized pituitary adenoma in the patients with CD was also investigated. **Results:** The basal ACTH inferior petrosal sinus:periphery (IPS:P) ratio was ≥ 2 in 63/74 patients with CD (85%), and in 1/10 EAS patients (10%); after stimulation with CRH, the ratio was ≥ 3 in 60/68 patients with CD (88%) and < 3 in all patients with EAS.

The basal and post-CRH ACTH IPS:P ratios had a diagnostic accuracy of 86% and 90% respectively. The diagnostic accuracy of IPSS with both ratios was significantly higher than magnetic resonance imaging (50%) and computed tomography (40%). The IPS:P ratio suggested by receiver-operator characteristic (ROC) analysis that better distinguished CD from EAS was 2.10 for the basal and 2.15 for the post-CRH ratios. Using these cut-offs, the specificity of basal ratio and the sensitivity of the post-CRH test rose to 100% and 93% respectively. Diagnostic accuracy remained substantially unchanged for the basal ratio (87% vs 86%), while it rose from 90% to 94% for the post-CRH ratio. The sensitivity of IPSS was significantly higher than that of magnetic resonance and computerized tomography.

IPSS was less reliable in identifying the adenoma site found at surgery than magnetic resonance imaging or computed tomography (65% vs 75% and 79% respectively).

Conclusion: In conclusion, IPSS improved the diagnostic performance of imaging techniques. It can help in excluding transsphenoidal surgery in EAS patients. More striking results were obtained when a $\geq 2.1 : 1$ basal ratio or a $\geq 2.15 : 1$ post-CRH ratio were considered as criteria to distinguish between patients with CD and EAS. To establish correctly the location of the pituitary adenoma, IPSS is less reliable than imaging techniques.

European Journal of Endocrinology 144 499–507

Introduction

Pituitary-dependent hypercortisolism accounts for over 70% of cases of Cushing's syndrome (1, 2). The differentiation between pituitary and ectopic adrenocorticotropin (ACTH) secretion is one of the most complex diagnoses in endocrine practice, and requires the integrated evaluation of biochemical tests and imaging techniques, none of which has a 100% diagnostic accuracy (3). The inferior petrosal sinus

(IPS) sampling (IPSS) was devised in an attempt to improve the diagnostic work-up of Cushing's syndrome (4–6). The rationale of this technique is that the pituitary gland drains directly into the IPSs, which are uncontaminated by blood deriving from different sources. Therefore, in Cushing's disease (CD), the concentration of ACTH is expected to be higher in the IPS draining the hemi-hypophysis bearing the tumor than in the contralateral IPS or in peripheral vessels (4–6). A ratio between IPS and peripheral basal ACTH

concentrations (IPS:P ratio) of 2:1 or greater is classically considered indicative of CD (6). If corticotropin-releasing hormone (CRH) is used to stimulate ACTH secretion during IPSS, an IPS:P ratio of 3:1 or greater is classically considered indicative of CD (6). In addition, a ratio between the right and left IPS of 1.4 or greater indicates that the adenoma is located on the corresponding side (7).

In early studies, IPSS was demonstrated to be a safe procedure (the only quite frequent untoward effect being transient ear discomfort) with an extremely high sensitivity and specificity, up to 100% (6), in differentiating pituitary from ectopic ACTH hypersecretion. Therefore, it was suggested that IPSS should be performed in all cases of suspected CD without radiological evidence of a pituitary tumor and in cases of suspected EAS without tumor visualization. In later studies, IPSS was demonstrated to be less reliable than formerly believed (3, 8–15) in the differential diagnosis of Cushing's syndrome. Moreover, IPSS was reported to predict the intra-pituitary tumor site with only an average 78% diagnostic accuracy (3, 16).

In this retrospective study, we re-evaluated the diagnostic accuracy of IPSS in 97 patients with ACTH hypersecretion admitted to various Endocrine Departments in Italy participating in a multicenter study of Cushing's syndrome.

Patients and methods

Patients

Ninety-seven patients were referred to the 20 participating centers between 1980 and 1998 for diagnosis and treatment of ACTH-dependent hypercortisolism. In all the patients IPSS had been correctly and successfully performed, i.e. with catheterization of both IPSs, after informed consent was obtained from all patients. Of the 97 patients, 74 (54 females, 20 males), aged between 12 and 64 years, had a confirmed diagnosis of CD, while EAS was ascertained in 10 patients (7 females, 3 males), aged between 18 and 65 years (Table 1). In

Table 1 Patients' profile. Data are presented as the mean \pm s.e.

	Cushing's disease	Ectopic ACTH secretion
Age (year)	39.3 \pm 7.2	35.5 \pm 8.6
Sex		
% female	73	70
% male	26	30
Hormonal assay		
Urinary free cortisol	242 \pm 25.2	308 \pm 41.1
Basal serum 0800 h cortisol	194.1 \pm 24	265.1 \pm 28
Basal plasma 0800 h ACTH	63.1 \pm 10	99 \pm 8.5

Hormonal values are expressed as percent of the upper limit of the normal range.

the remaining 13 patients, CD was not confirmed by surgical and/or radiotherapy outcome and they were, therefore, excluded from the study. However, 12 of these patients had an endocrine profile suggestive of CD and 1 had an endocrine profile suggestive of EAS.

The criteria consistent with the diagnosis of ACTH-dependent Cushing's syndrome were: (1) increase of daily urinary cortisol excretion; (2) increase of basal serum cortisol concentrations with lack of the physiological circadian rhythm and inappropriately elevated plasma ACTH levels; (3) absence of urinary and serum cortisol suppression after low-dose dexamethasone test. A decrease in urinary or serum cortisol levels greater than 50% of baseline values after high-dose dexamethasone test and an increase of plasma ACTH levels after 100 μ g CRH greater than 50% of baseline values suggested the diagnosis of Cushing's disease rather than ectopic ACTH syndrome.

The final study population consisted of 74 patients with CD and 10 patients with EAS.

The diagnosis of CD or EAS was confirmed in the current study in accordance with Invitti *et al.* (17), by the following criteria: (a) The removal of a pituitary tumor at transsphenoidal surgery with pathology indicative of adenoma or hyperplasia, and positive immunohistochemical ACTH staining (69 subjects) was considered diagnostic of CD. (b) If no pituitary tumor was identified during transsphenoidal surgery, a pituitary source of ACTH was considered proven in patients who showed clinical and hormonal remission of hypercortisolism after transsphenoidal surgery or pituitary irradiation (5 subjects). In fact, a considerable proportion of patients with CD may display normal pituitary histology (18). (c) EAS was proven in patients who underwent resection of an extra-pituitary tumor with positive staining for ACTH (10 subjects).

All centers participating in the study were required to record the IPS:P ratio and the inter-sinus ACTH ratio before and 2, 5, 10 and 15 min after the administration of 100 μ g ovine or human CRH, as well as the results of pituitary imaging, pituitary surgery, pathological studies of the pituitary adenoma and success of the surgical treatment. The basal ACTH IPS:P ratio was available in all 84 patients, while the post-CRH ACTH IPS:P ratio was available in 78 (68 CD and 10 EAS) patients. The basal inter-sinus ratio was available in all 74 patients with CD.

Pituitary magnetic resonance and computerized tomography imaging were available in 70 and 42 patients respectively.

Pituitary surgery was successful in 62 of 74 patients with CD (84%). Prolonged follow-up (at least 12 months) was recorded in all patients.

IPSS procedure

All the centers participating in this study used the standard IPSS technique described by Oldfield *et al.* (6).

Briefly, bilateral and simultaneous IPSS was performed using a percutaneous approach, after systemic anticoagulation with heparin. Contrast medium was injected to verify the position of the catheters in the IPS. ACTH was measured in blood simultaneously obtained from the IPS and from a peripheral vein. Ovine or human CRH (100 µg) was then infused (1 min) into a peripheral vein, and 2-, 5- and 10-min samples were obtained simultaneously from both the IPSs and the peripheral vein. Retrograde venography was performed through each catheter after blood sampling to verify correct position of the catheter. The ACTH concentration ratio between the right and left IPSs and peripheral blood was calculated for each set of samples, and the maximal ratio (right or left sinus) identified. A maximal ratio of ≥ 2 before or ≥ 3 after CRH stimulation indicated Cushing's disease. To establish lateralization of the adenoma in Cushing's disease, the right and left IPS or *vice versa* ACTH ratio, i.e. the inter-sinus ratio, was calculated. A maximal ratio of ≥ 1.4 either before or after CRH stimulation predicted the side of the pituitary adenoma.

Adverse events included ear discomfort in 65% of cases and hematoma at the site of catheter insertion in 8% of cases.

Imaging procedures

Pituitary imaging was performed by computerized tomography and/or magnetic resonance, as described by Invitti *et al.* (17). A pituitary tumor was diagnosed when a focal defect was identified, either isolated or associated with swelling of the sellar diaphragm or deviation of the pituitary stalk.

Assays

Plasma ACTH concentrations were measured in-house by each center using commercially available radioimmunoassays (Byk Gulden, Dietzenbach, Germany; Medgenix, Brussels, Belgium; Sorin, Saluggia, Italy; INCSTAR Corp., Stillwater, MN, USA; intra- and interassay coefficients of variation ranged from 5.5 to

9.5% and from 5.8 to 12.5% respectively; sensitivity, 8 or 10 pg/ml) or immunoradiometric assays (Nichols, San Juan Capistrano, CA, USA; CIS-Bio International, Gif-sur-Yvette Cedex, France; intra- and interassay coefficients of variation ranged from 2.1 to 5.3% and from 3.1 to 8.9% respectively; sensitivity, 2 or 5 pg/ml). Serum and urinary cortisol levels were measured by commercially available RIAs. Since different reference ranges were reported by each center, baseline ACTH and serum and urinary cortisol concentrations were considered as a percentage of the upper limit of the normal range.

Statistical analysis

The SPSS package for Windows version 8.0 (Cary, NC, USA) was used for statistical analyses. Sensitivity, specificity, diagnostic accuracy, and positive and negative predictive values of tests were calculated according to standard statistical formulas. The comparison between the categorical data were performed by χ^2 test with the Yates correction or Fisher's exact test where appropriate. The *P* values were given for these analyses. Significance was set at 5%. IPS:P ratios were evaluated by receiver-operator characteristic (ROC) curves to determine optimal diagnostic cut-offs.

Results

Hormonal data

Basal plasma ACTH, serum cortisol and urinary free cortisol concentrations were higher in patients with EAS than in those with CD (Table 1), but a large overlap existed between groups (Fig. 1).

IPSS results (Table 2)

The basal ACTH IPS:P ratio was ≥ 2 in 63 of 74 CD patients and was < 3 in 9 of 10 EAS patients. Upon stimulation with CRH, the ACTH IPS:P ratio was ≥ 3 in 60 of 68 CD patients and < 3 in all 10 EAS patients (Fig. 2). Among the 78 patients submitted to both basal and stimulated IPSS, the basal ACTH IPS:P ratio was

Table 2 Diagnostic performance of basal and post-CRH IPSS, magnetic resonance and computed tomography in the differential diagnosis of ACTH-dependent Cushing's syndrome.

	No. of patients	Sensitivity (%)	Specificity (%)	Diagnostic accuracy (%)	Positive predictive value (%)	Negative predictive value (%)
Basal IPS:P ratio ≥ 2	84	85 ^{a,b}	90	86 ^{e,f}	98	45
CRH IPS:P ratio ≥ 3	78	88 ^{c,d}	100	90 ^{g,h}	100	55
Magnetic resonance	70	45	87	50	96	17
Computed tomography	42	37	75	40	93	11

^a $\chi^2 = 4.403$, $P < 0.05$; ^b $\chi^2 = 4.911$, $P < 0.05$; ^c $\chi^2 = 4.820$, $P < 0.05$; ^d $\chi^2 = 5.284$, $P < 0.05$; ^e $\chi^2 = 3.751$, $P < 0.05$; ^f $\chi^2 = 4.615$, $P < 0.05$; ^g $\chi^2 = 4.375$, $P < 0.05$; ^h $\chi^2 = 5.181$, $P < 0.05$.

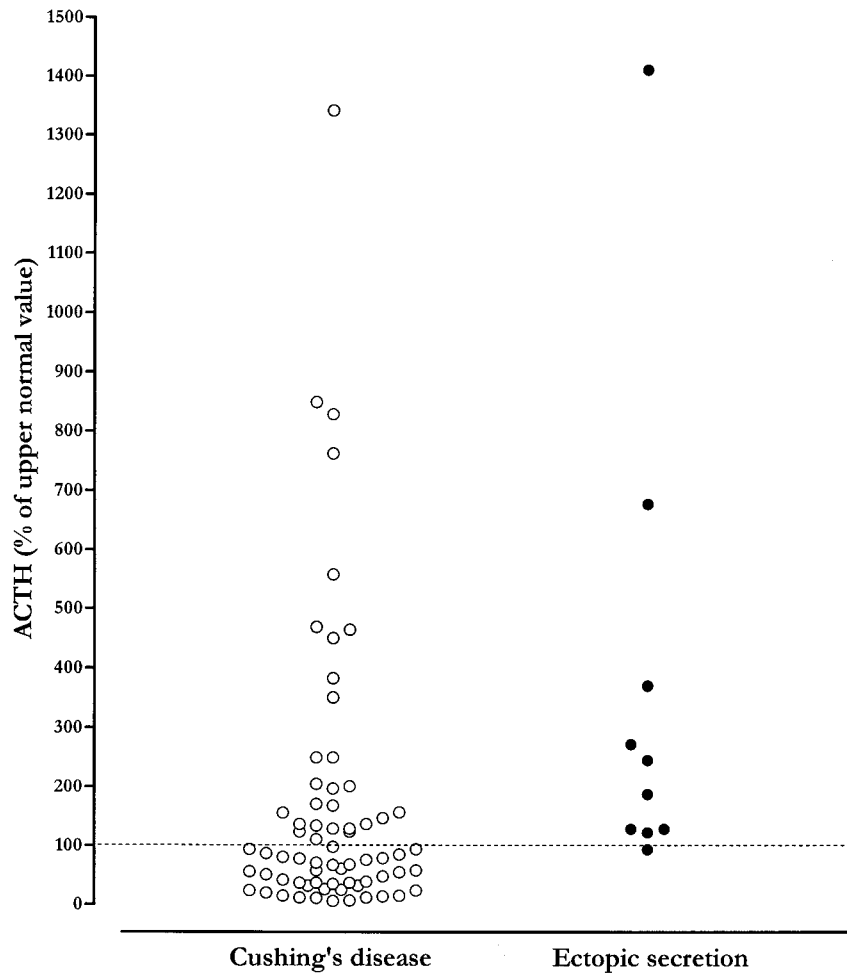


Figure 1 Plasma ACTH levels in patients with ACTH-dependent Cushing's syndrome, expressed as a percentage of the upper limit of the normal range.

≥ 2 or the post-CRH ratio was ≥ 3 in 65 of 68 CD patients, and it was < 2 at basal assessment or < 3 at post-CRH assessment in all 10 EAS patients.

Imaging techniques results (Table 2)

Of the 70 patients for whom pituitary magnetic resonance was performed, micro- and macroadenoma were detected in 27 patients and 1 patient, respectively, of the 62 with proven CD. A microadenoma was detected in 1 of 8 patients with EAS. No tumor was detected in the remaining 34 CD patients or 7 EAS patients. Of the 42 patients with pituitary computerized tomography findings, micro- and macroadenoma were identified in 13 and 1, respectively, of the 38 patients with proven CD. A microadenoma was detected in 1 of 4 patients with EAS. No tumor was found in the remaining 24 CD patients or 3 EAS patients.

IPSS vs pituitary imaging techniques performance (Table 2)

IPSS had a significantly higher sensitivity and diagnostic accuracy than pituitary imaging. The post-CRH ACTH IPS:P ratio had a diagnostic accuracy higher than the basal ratio. Specificity, and negative and positive predictive values were not significantly different for IPSS and pituitary imaging.

ROC analysis

The IPS:P ratio that better distinguished CD from EAS was 2.1:1 for the basal ratio and 2.15:1 for the post-CRH ratio (Fig. 3). Using these cut-offs, the specificity of the basal ratio and the sensitivity of the post-CRH test rose to 100% and 93% respectively (Table 3). Diagnostic accuracy remained substantially unchanged for the basal ratio (87% vs 86%), while it rose from 90% to 94% for the post-CRH ratio (Table 3).

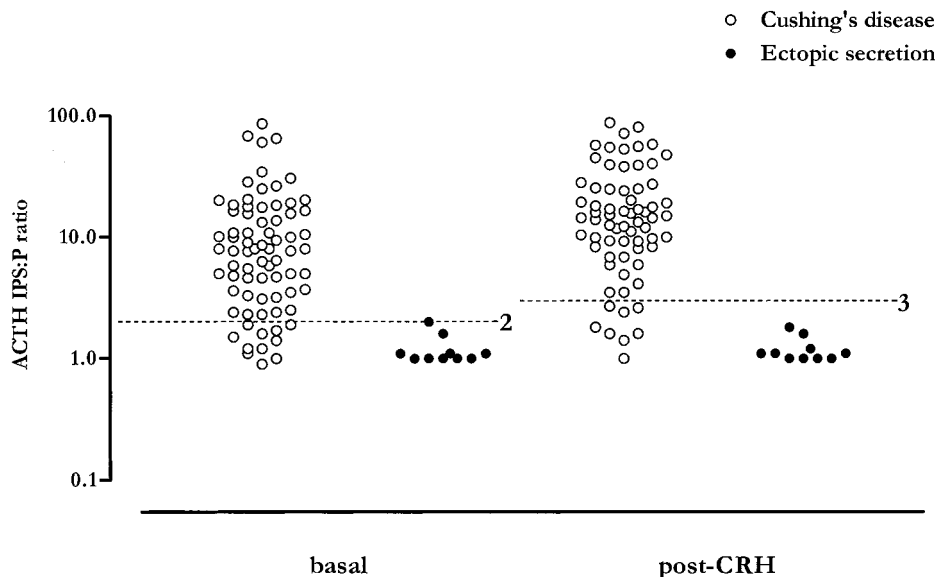


Figure 2 Maximal ratio of ACTH levels in one inferior petrosal sinus and in the periphery (IPS:P) in patients with Cushing's syndrome. The dashed lines identify the IPS:P values 2 and 3, for the basal and the post-CRH ratios respectively.

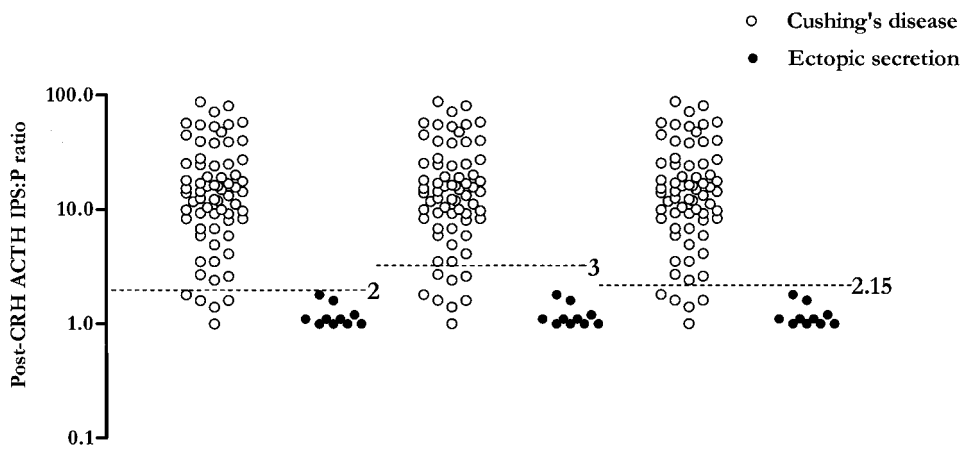


Figure 3 Maximal ratio of ACTH levels in one inferior petrosal sinus and in the periphery (IPS:P) upon stimulation with CRH in patients with Cushing's syndrome. The dashed lines identify the IPS:P values 2, 2.15 and 3 respectively.

Table 3 Diagnostic performance of basal, post-CRH and cumulative IPSS in the differential diagnosis of ACTH-dependent Cushing's syndrome: standard cut-offs (≥ 2 , ≥ 3 for basal and CRH IPS:P ratio respectively) compared with cut-offs resulting from ROC analysis (≥ 2.1 , ≥ 2.15 for basal and CRH IPS:P ratio respectively).

	No. of patients	Sensitivity (%)	Specificity (%)	Diagnostic accuracy (%)	Positive predictive value (%)	Negative predictive value (%)
Basal IPS:P ratio ≥ 2	84	85	90	86	98	45
CRH IPS:P ratio ≥ 3	78	88	100	90	100	55
Basal ≥ 2 or CRH ≥ 3 IPS:P ratio	78	96	100	96	100	77
Basal IPS:P ratio ≥ 2.1	84	85	100	87	100	48
CRH IPS:P ratio ≥ 2.15	78	93	100	94	100	67
Basal ≥ 2.1 or CRH ≥ 2.15 IPS:P ratio	78	96	100	96	100	77

In the 78 CD patients with both basal and stimulated IPSS findings, the cumulative diagnostic accuracy was slightly but not significantly higher than that of the basal or the post-CRH IPSS alone (Table 3).

Tumor lateralization

An ACTH inter-sinus ratio > 1.4 was found in 58% of patients, either at basal evaluation or after CRH stimulation. The site of the adenoma as predicted by IPSS, magnetic resonance and computerized tomography was in agreement with surgical evidence in 65%, 75% and 79% of cases respectively. Concordance between basal and post-CRH inter-sinus gradients was 87%. Among the 5 discordant cases, the affected side of the pituitary gland was correctly predicted by the basal inter-sinus gradient in 3 cases and by the post-CRH inter-sinus gradient in the remaining 2 cases.

No significant correlation was found between either basal or post-CRH ACTH IPS:P gradient and surgical success.

Discussion

In this retrospective multicenter study, the sensitivity and specificity of IPSS in CD and EAS are considerably higher than pituitary imaging procedures. Those results are in line with previous data (3). However, the basal and post-CRH ACTH IPS:P ratios that better distinguished between pituitary and ectopic ACTH secretion were closer to those proposed by Findling (5) than to those subsequently reported by Oldfield and classically used in most reports on IPSS accuracy (6). Conversely to that previously reported, in this study CRH compared with basal evaluation did not improve significantly the diagnostic accuracy of IPSS. Radiological imaging, although less sensitive than IPSS in diagnosing CD, was more accurate than IPSS in localizing the intra-pituitary site of the tumor. As the present study was a multicenter one, it has to be considered that different IPSS operators were involved and different CRH preparations and hormonal assay procedures were used in each of the centers participating in the study.

Pituitary imaging, and even the newly introduced dynamic magnetic resonance procedures, fail to identify pituitary tumors in as many as 50% of CD patients (19, 20). This is probably due to the very small size of ACTH-secreting adenomas. Selective sampling from the IPS was a welcome addition to the diagnostic tools in ACTH-dependent hypercortisolism (4, 5). IPSS was reported to have high specificity and positive predictive value (6, 21–23), although false positive results have also been reported (12, 15). These could be due to the lack of hypercortisolism when IPSS was performed, due to cyclical secretion of CRH/ACTH, or application of cortisol-lowering drugs, which depress the normal corticotroph population and

increase the sensitivity of ACTH to CRH administration. Furthermore, concomitant secretion of ACTH and CRH by a neuroendocrine tumor may also result in biochemical tests and IPSS outcomes consistent with CD (15). In the current study, no false positive cases were found. Among the 10 patients with EAS, only one was not correctly identified using the basal ACTH IPS:P ratio, resulting, instead, in being correctly diagnosed using the post-CRH ACTH IPS:P ratio. However, specificity was raised from 90% to 100% when the 2.1:1 instead of the 2:1 ratio was adopted. In this study, the diagnostic accuracy of both basal and post-CRH IPSS was not significantly different, although it was higher in the first than in the second case. This result was confirmed when the cut-offs suggested by the ROC analysis were utilized.

In the current study, IPSS had a significantly higher sensitivity than conventional imaging procedures. IPSS also had a negative predictive value higher than the imaging procedures, although the resulting difference was not significant. However, the prevalence of misdiagnosed CD patients was still higher compared with that reported by the most important studies (3). It may be argued that our data could have been distorted by the exclusion of 13 patients with unconfirmed diagnosis. When these patients were classified according to the results of high-dose dexamethasone suppression test and CRH stimulation test, the results of IPSS confirmed the diagnosis of CD in 12 of them. Thus, the diagnostic accuracy of IPSS calculated for the 97 patients as a whole was identical to that calculated in the subgroup of 84 patients (87% vs 86%). Anyway, the possibility that an incorrect use or interpretation of biochemical and hormonal tests performed before the IPSS could have influenced the IPSS outcome in such a large cohort of patients cannot be excluded.

How can the false negative results of IPSS be explained? Doppman *et al.* (24), reviewing retrograde IPS venograms of 501 patients with surgically proven CD and negative pituitary imaging, reported that all the patients with false negative results had a hypoplastic or plexiform IPS ipsilateral to the adenoma. An alternative explanation is a potential additional drainage through the portal sinuses, ascending through the pituitary stalk into the hypothalamus (25). Thus, sampling errors may occur due to dilution of pituitary blood from non-pituitary sources consequent to extensive anastomosis between the IPS and the basilar venous plexus, retrograde drainage of superior petrosal sinus, or misplaced catheters (26). Therefore, even when venous angiography shows correct positioning of the catheter, there is no definitive proof of correct sampling of pituitary blood from both IPSs. When the new cut-offs suggested by ROC analysis were used, only a modest improvement of sensitivity and negative predictivity was observed, demonstrating that false negative results affect IPSS performance in any case, probably due to the above-mentioned anatomical anomalies. Since IPS

venograms were not performed in each patient in our study, our results can neither confirm nor deny the previous hypotheses.

To ameliorate the diagnostic power of IPSS we calculated the cumulative diagnostic accuracy. This appeared to be a more reliable test than the single basal or stimulated ratio, because the patients with proven CD not recognised by ≥ 2 basal gradient or ≥ 3 post-CRH gradient were reduced to only 3 among 68. This result was obtained using both the standard cut-offs and those obtained by the ROC analysis. Therefore, the CRH test, introduced in the IPSS procedure to create an ACTH pulse and thus minimize the IPS:P ratio distortion due to interpulse intervals (6, 27), seems to achieve the maximal sensitivity, negative predictivity and diagnostic accuracy when the cumulative response to both basal and stimulated test was used. The diagnostic accuracy of IPSS seems to be further improved by using a combined stimulus with CRH and desmopressin (28).

The diagnostic accuracy of IPSS in identifying the side of the pituitary tumor was 65% in the current study, slightly lower than previously reported (3, 16). However, controversial results have been reported on this issue. IPSS was unsuccessful in several studies and highly successful in others (3, 16). A partial explanation for this discrepancy could be the mixing of blood from the two sides of the anterior pituitary (26). Recently, it was reported that cavernous sinus venography revealed asymmetric drainage from cavernous sinuses to IPSS (29). In most cases, this causes blood drainage from both cavernous sinuses into a single IPS, thereby distorting the result of the inter-sinus ratio. Mamelak *et al.* (29) reported that IPSS correctly indicated the position of the tumor in all patients with symmetric drainage. Therefore, cavernous venography has been proposed for all patients undergoing venous sampling of ACTH (29). Cavernous sinus sampling has been reported to be a better predictor of the intra-pituitary tumor localization and to have the same accuracy as IPSS in differentiating between pituitary and ectopic ACTH secretion (30, 31). However, because of its higher cost and greater risk of adverse events, cavernous sinus sampling is not recommended at present (32).

Reversal of the inter-sinus ratio between pre- and post-CRH values has been reported (7, 10, 33): in our series basal vs post-CRH inter-sinus ratio concordance was found in 87% of cases. Among the 5 cases with reversed inter-sinus ratio, the correct side was indicated by the basal ratio in 3 cases. The CRH test did not significantly improve the diagnostic accuracy of adenoma localization. Taken together, these results confirm that IPSS is less reliable than magnetic resonance and computerized tomography in predicting the location of the adenoma in the pituitary gland.

Because IPSS is an invasive test, it should be used with caution. Although extremely rare (prevalence

about 0.2%), brain-stem vascular damage and transient or permanent neurological impairment can occur (34, 35). However, in most cases, IPSS causes only minor complications such as hematomas, vasovagal reaction (36) or transient ear discomfort. Because hypercortisolemic patients have notable vascular fragility and dramatically increased blood coagulability (37, 38), heparin should be given to prevent thrombotic events. Injury to the vascular wall with subsequent thrombosis is the hypothesized cause of venous thromboembolism after IPSS in one patient (39, 40). Given the unlikely but possible fatal complications, IPSS should be performed in centers experienced in the technique, where the safety of this procedure is greatly elevated.

In conclusion, this multicenter study on the diagnostic accuracy of IPSS in CD showed that IPSS has a high specificity; thus no patient with extra-pituitary Cushing's syndrome risks being submitted to transphenoidal surgery, although there is a percentage of false negative results. Hence, caution must be exerted in excluding CD in the presence of hormonal and radiological findings consistent with this diagnosis (22, 41). On the basis of the ROC analysis, we suggest that all subjects with $\geq 2.1 : 1$ basal ratio or $\geq 2.15 : 1$ post-CRH ratio are considered as true positives. The lateralizing gradient can guide the surgeon to the correct side of the pituitary gland affected by the tumor, taking into consideration that the indication is mistaken in 35% of cases. IPSS did not predict surgical outcome. Therefore, IPSS is useful to distinguish CD from EAS, but it should be restricted to cases with conflicting hormonal and radiological findings. Finally, although rare, severe adverse reactions can occur during the procedure and thus IPSS should be performed only in specialized referral centers.

Acknowledgements

The Study Group of the Italian Endocrinology Society on the Pathophysiology of the Hypothalamic–Pituitary–Adrenal Axis consists of: A Angeli and M Terzolo, Second Dept. of Internal Medicine, Turin University, Orbassano (Turin); G Belotti and R Castello, Dept. of Endocrinology, Ospedale Maggiore, Verona; F Bertolissi, Ospedale Civile, Udine; G Borretta, Ospedale S. Croce e Carle, Cuneo; M Boscaro and E Scarpa, Institute of Semeiotics, Padua University; F Camanni and E Mazza, Endocrinology Dept., Ospedale Le Molinette, Turin University; L Cantalamessa, First Dept. of Internal Medicine, Milan University; F Caviezel and L Morricone, Institute of Medical and Surgical Sciences, S. Donato Milanese, Milan University; C De Sanctis, Dept. of Pediatric Endocrinology, Ospedale Infantile Regina Margherita, Turin; E Degli Uberti, Endocrinology Section, Dept. of Biomedical Sciences and Advanced Therapy, Ferrara University; C Ferrari, Ospedale Fatebenefratelli, Milan; A Giustina, Dept. of Internal

Medicine, Brescia University; A Janni and R Lo Coco, Dept. of Endocrinology, Ospedale 'V. Cervello', Palermo; C Letizia, Second Institute of Internal Medicine, Policlinico Umberto I, Rome; A Liuzzi and M R Ghiggi, Ospedale Casa Sollievo della Sofferenza, Dept. of Endocrinology, S. Giovanni Rotondo (Foggia); V Lo Cascio and G Francia, Dept. of Internal Medicine, Verona University; A Mancini and L De Marinis, Dept. of Endocrinology, Rome University; M Mannelli, Dept. of Clinical Pathophysiology, Florence University; F Mantero and A M Masini, Dept. of Endocrinology, Ancona University; C Mazzi, Dept. of Endocrinology, Ospedale S. Antonio Abate, Gallarate (Varese); M Mugge and P Moghetti, Dept. of Metabolic Diseases, Verona University; A Pinchera, E Martino and D Barletta, Dept. of Endocrinology, Pisa University, Tirrenia (Pisa); G Rizzi, Inst. of Internal Medicine, Ospedale Civile, Saluzzo (Cuneo); F Santeusano, Dept. of Internal Medicine and Endocrinology and Metabolic Sciences, Perugia University; F Sciarra and C Tosti-Croce, 3rd Dept. of Endocrinology, 'La Sapienza' University, Rome; P Vezzadini and R Toni, Dept. of Internal Medicine, Ospedale Bellaria, Bologna University; G A Zampa and A Sforza, Dept. of Endocrinology and Metabolic Sciences, Ospedale Maggiore, Bologna.

References

- Aron DC, Findling JW & Tyrrel JB. Cushing's disease. *Endocrinology and Metabolism Clinics of North America* 1987 **16** 705–730.
- Orth DN. Cushing's syndrome. *New England Journal of Medicine* 1995 **332** 791–803.
- Newell-Price J, Trainer P, Besser M & Grossman A. The diagnosis and differential diagnosis of Cushing's syndrome and pseudo-Cushing's state. *Endocrine Review* 1998 **19** 647–672.
- Corrigan DE, Schaaf M, Whaley RA, Czerwinski CL & Earll JM. Selective venous sampling to differentiate ectopic ACTH secretion from pituitary Cushing's syndrome. *New England Journal of Medicine* 1977 **296** 861–862.
- Findling JW, Aron DC, Tyrrell JB, Shinsako JH, Fitzgerald PA, Norman D *et al.* Selective venous sampling for ACTH in Cushing's syndrome: differentiation between Cushing's disease and the ectopic ACTH syndrome. *Annals of Internal Medicine* 1981 **94** 647–652.
- Oldfield EH, Doppman JL, Nieman LK, Chrousos GP, Miller DL, Katz DA *et al.* Petrosal sinus sampling with and without corticotropin-releasing hormone for the differential diagnosis of Cushing's syndrome. *New England Journal of Medicine* 1991 **325** 897–905.
- Oldfield EH, Chrousos GP, Schulte HM, Schaaf M, McKeever PE, Krudy AG *et al.* Preoperative lateralization of ACTH-secreting pituitary microadenomas by bilateral and simultaneous inferior petrosal venous sinus sampling. *New England Journal of Medicine* 1985 **312** 100–103.
- Boscaro M, Rampazzo A, Paoletta A, Roseano P, Pagotto U, Fallo F *et al.* Selective venous sampling in the differential diagnosis of ACTH-dependent Cushing's syndrome. *Neuroendocrinology* 1992 **55** 264–268.
- Colao A, Merola B, Tripodi FS, Di Sarno A, Esposito V, Marzullo P *et al.* Simultaneous and bilateral inferior petrosal sinus sampling for the diagnosis of Cushing's syndrome: comparison of multi-hormonal assay, baseline multiple sampling and ACTH-releasing hormone test. *Hormone Research* 1993 **40** 209–216.
- de Herder WW, Uitterlinden P, Pieterman H, Tanghe HJ, Kwekkeboom DJ, Pols HAP *et al.* Pituitary tumor localization in patients with Cushing's disease by magnetic resonance imaging. Is there a place for petrosal sinus sampling? *Clinical Endocrinology* 1994 **40** 87–92.
- Zarrilli L, Colao A, Merola B, La Tessa G, Spaziante R, Tripodi F *et al.* Corticotropin-releasing hormone test: improvement of the diagnostic accuracy of simultaneous and bilateral inferior petrosal sinus sampling in patients with Cushing's syndrome. *World Journal of Surgery* 1995 **19** 150–153.
- Yamamoto Y, Davis DH, Nippoldt TB, Young WF Jr, Huston J III & Parisi JE. False-positive inferior petrosal sinus sampling in the diagnosis of Cushing's disease. Report of two cases. *Journal of Neurosurgery* 1995 **83** 1087–1091.
- Lopez J, Barcelo B, Lucas T, Salame F, Alameda C, Boronat M *et al.* Petrosal sinus sampling for diagnosis of Cushing's disease: evidence of false negative results. *Clinical Endocrinology* 1996 **45** 147–156.
- Heppner C, Becker K, Saeger W, Günter RW, Allolio B, Krone W *et al.* Occult ectopic Cushing's syndrome failure of simultaneous bilateral petrosal sinus sampling in the differential diagnosis of ACTH-dependent Cushing's syndrome. *European Journal of Endocrinology* 1997 **137** 74–78.
- Young J, Deneux C, Grino M, Oliver C, Chanson P & Schaison G. Pitfall of petrosal sinus sampling in a Cushing's syndrome secondary to ectopic adrenocorticotropin-corticotropin-releasing hormone (ACTH-CRH) secretion. *Journal of Clinical Endocrinology and Metabolism* 1998 **83** 305–308.
- Booth GL, Redelmeier DA, Grosman H, Kovacs K, Smyth HS & Ezzat S. Improved diagnostic accuracy of inferior petrosal sinus sampling over imaging for localization pituitary pathology in patients with Cushing's disease. *Journal of Clinical Endocrinology and Metabolism* 1998 **83** 2291–2295.
- Invitti C, Pecori Giraldi F, De Martin M, Cavagnini F and the Study Group of the Italian Society of Endocrinology on the Pathophysiology of the Hypothalamic–Pituitary–Adrenal Axis. Diagnosis and management of Cushing's syndrome: results of an Italian Multicentre Study. *Journal of Clinical Endocrinology and Metabolism* 1999 **84** 440–448.
- Kovacs K. The pathology of Cushing's disease. *Journal of Steroid Molecular Biology* 1993 **45** 179–182.
- Doppman JL, Frank JA, Dwyer AJ, Oldfield EH, Miller DL, Nieman LK *et al.* Gadolinium DTPA enhanced MR imaging of ACTH-secreting microadenomas of the pituitary gland. *Journal of Computer Assisted Tomography* 1998 **12** 728–735.
- Tabarin A, Laurent F, Catargi B, Olivier-Puel F, Lescene R, Berge J *et al.* Comparative evaluation of conventional and dynamic magnetic resonance imaging of the pituitary gland for the diagnosis of Cushing's disease. *Clinical Endocrinology* 1998 **49** 293–300.
- Kaltsas GA, Giannulis MG, Newell-Price JDC, Dacie JE, Thakkar C, Afshar F *et al.* A critical analysis of the value of simultaneous inferior petrosal sinus sampling in Cushing's disease and the occult ectopic adrenocorticotropin syndrome. *Journal of Clinical Endocrinology and Metabolism* 1999 **84** 487–492.
- Wiggam MI, Heaney AP, McIlrath EM, McCance DR, Sheridan B, Hadden DR *et al.* Bilateral inferior petrosal sinus sampling in the differential diagnosis of adrenocorticotropin-dependent Cushing's syndrome: a comparison with other diagnostic tests. *Journal of Clinical Endocrinology and Metabolism* 2000 **85** 1525–1532.
- Findling JW. Inferior petrosal sinus sampling: pros and cons, when and where. *Journal of Endocrinological Investigation* 2000 **23** 193–195.
- Doppman JL, Chang R, Oldfield EH, Chrousos G, Stratakis CA & Nieman LK. The hypoplastic inferior petrosal sinus: a potential source of false-negative results in petrosal sampling for Cushing's disease. *Journal of Clinical Endocrinology and Metabolism* 1999 **84** 533–540.

- 25 Bergland RM & Page RB. Can the pituitary secrete directly to the brain? (affirmative anatomical evidence). *Endocrinology* 1978 **102** 1325–1338.
- 26 Doppman JL, Krudy AG, Girton ME & Oldfield EH. Basilar venous plexus of the posterior fossa: a potential source of error in petrosal sinus sampling. *Radiology* 1985 **155** 375–378.
- 27 Chrousos GP, Schuermeyer TH, Doppman J, Oldfield EH, Schulte HM, Gold PW *et al.* Clinical applications of corticotrophin-releasing-factor. *Annals of Internal Medicine* 1985 **102** 344–358.
- 28 Tsagarakis S, Kaskarelis IS, Kokkoris P, Malagari C & Thalassinou N. The application of a combined stimulation with CRH and desmopressin during bilateral inferior petrosal sinus sampling in patients with Cushing's syndrome. *Clinical Endocrinology* 2000 **52** 355–361.
- 29 Mamelak AN, Dowd CE, Tyrrell JB, McDonald JF & Wilson CB. Venous angiography is needed to interpret inferior petrosal sinus and cavernous sinus sampling data for lateralizing adrenocorticotropin-secreting adenomas. *Journal of Clinical Endocrinology and Metabolism* 1996 **81** 475–481.
- 30 Graham KE, Samuels MH, Nesbit GM, Cook DM, O'Neill OR, Barnwell SL *et al.* Cavernous sinus sampling is highly accurate in distinguishing Cushing's disease from the ectopic adrenocorticotropin syndrome and in predicting intrapituitary tumor location. *Journal of Clinical Endocrinology and Metabolism* 1999 **84** 1602–1610.
- 31 Teramoto A, Nemoto S, Takakura K, Sasaki Y & Machida T. Selective venous sampling directly from cavernous sinus in Cushing's syndrome. *Journal of Clinical Endocrinology and Metabolism* 1993 **76** 637–641.
- 32 Doppman JL, Nieman LK, Chang R, Yanovski J, Cutler GB Jr, Chrousos GP *et al.* Selective venous sampling from the cavernous sinuses is not a more reliable technique than sampling from the inferior petrosal sinuses in Cushing's syndrome. *Journal of Clinical Endocrinology and Metabolism* 1995 **80** 2485–2489.
- 33 Miller DL, Doppman JL, Nieman LK, Cutler GB Jr, Chrousos GP, Loriaux DL *et al.* Petrosal sinus sampling: discordant lateralization of ACTH-secreting pituitary microadenomas before and after stimulation with corticotropin-releasing hormone. *Radiology* 1990 **176** 429–431.
- 34 Lefournier V, Gatta B, Martinie M, Vasdev A, Tabarin A, Bessou P *et al.* One transient neurological complication (sixth nerve palsy) in 166 consecutive inferior petrosal sinus samplings for the etiological diagnosis of Cushing's syndrome. *Journal of Clinical Endocrinology and Metabolism* 1999 **84** 3401–3402.
- 35 Bonelli FS, Huston J, Meyer FB & Carpenter PC. Venous subarachnoid hemorrhage after inferior petrosal sinus sampling for adrenocorticotropin hormone. *American Journal of Neuroradiology* 1999 **20** 306–307.
- 36 Sturrok ND & Jeffcoate WJ. A neurological complication of inferior petrosal sinus sampling during investigation for Cushing's disease: a case report. *Journal of Neurology, Neurosurgery and Psychiatry* 1997 **62** 527–528.
- 37 Colao A, Pivonello R, Spiezia S, Faggiano A, Ferone D, Filippella M *et al.* Persistence of increased cardiovascular risk in patients with Cushing's disease after 5 years of successful cure. *Journal of Clinical Endocrinology and Metabolism* 1999 **84** 2664–2672.
- 38 Patrassi GM, Sartori MT, Viero ML, Scarano L, Boscaro M & Girolami A. The fibrinolytic potential in patients with Cushing's syndrome: a clue to their hypercoagulable state. *Blood Coagulation and Fibrinolysis* 1992 **3** 789–793.
- 39 Obuobie K, Davies JS, Ogunko A & Scanlon MF. Venous thromboembolism following inferior petrosal sinus sampling in Cushing's disease. *Journal of Endocrinological Investigation* 2000 **23** 542–544.
- 40 Diez JJ & Iglesias P. Pulmonary thromboembolism after inferior sinus sampling in Cushing's syndrome. *Clinical Endocrinology* 1997 **46** 777.
- 41 Pecori Giraldo F, Invitti C & Cavagnini F. Inferior petrosal sinus sampling ten years down the road. *Journal of Endocrinological Investigation* 2000 **23** 325–327.

Received 2 November 2000

Accepted 5 February 2001