

The New England Journal of Medicine

© Copyright, 1998, by the Massachusetts Medical Society

VOLUME 338

JANUARY 8, 1998

NUMBER 2



RELATION BETWEEN THERAPY FOR HYPERTHYROIDISM AND THE COURSE OF GRAVES' OPHTHALMOPATHY

LUIGI BARTALENA, M.D., CLAUDIO MARCOCCI, M.D., FAUSTO BOGAZZI, M.D., LUCA MANETTI, M.D.,
MARIA LAURA TANDA, M.D., ENRICA DELL'UNTO, M.D., GABRIELLA BRUNO-BOSSIO, M.D., MARCO NARDI, M.D.,
MARIA PIA BARTOLOMEI, M.D., ANTONIO LEPRI, M.D., GIUSEPPE ROSSI, PH.D., ENIO MARTINO, M.D.,
AND ALDO PINCHERA, M.D.

ABSTRACT

Background The chief clinical characteristics of Graves' disease are hyperthyroidism and ophthalmopathy. The relation between the two and the effect of treatment for hyperthyroidism on ophthalmopathy are unclear.

Methods We studied 443 patients with Graves' hyperthyroidism and slight or no ophthalmopathy who were randomly assigned to receive radioiodine, radioiodine followed by a 3-month course of prednisone, or methimazole for 18 months. The patients were evaluated for changes in the function and appearance of the thyroid and progression of ophthalmopathy at intervals of 1 to 2 months for 12 months. Hypothyroidism and persistent hyperthyroidism were promptly corrected.

Results Among the 150 patients treated with radioiodine, ophthalmopathy developed or worsened in 23 (15 percent) two to six months after treatment. The change was transient in 15 patients, but it persisted in 8 (5 percent), who subsequently required treatment for their eye disease. None of the 55 other patients in this group who had ophthalmopathy at base line had improvement in their eye disease. Among the 145 patients treated with radioiodine and prednisone, 50 (67 percent) of the 75 with ophthalmopathy at base line had improvement, and no patient had progression. The effects of radioiodine on thyroid function were similar in these two groups. Among the 148 patients treated with methimazole, 3 (2 percent) who had ophthalmopathy at base line improved, 4 (3 percent) had worsening of eye disease, and the remaining 141 had no change.

Conclusions Radioiodine therapy for Graves' hyperthyroidism is followed by the appearance or worsening of ophthalmopathy more often than is therapy with methimazole. Worsening of ophthalmopathy after radioiodine therapy is often transient and can be prevented by the administration of prednisone. (N Engl J Med 1998;338:73-8.)

©1998, Massachusetts Medical Society.

THE relation between the treatment of hyperthyroidism due to Graves' disease and the course of Graves' ophthalmopathy is a matter of controversy.¹ Antithyroid-drug treatment appears not to be associated with the development or worsening of preexisting eye disease.² The effect of thyroidectomy is less clear, but in general it probably does not induce or worsen eye disease.³⁻⁵ In contrast, the effects of radioiodine therapy are less clear; ocular improvement, worsening of eye disease, and no change have been reported in different studies.⁴ To address this question, we undertook a prospective, randomized study of the effects of the treatment of Graves' hyperthyroidism with methimazole or radioiodine therapy, as well as the effects of glucocorticoids, in patients with mild or moderate Graves' ophthalmopathy or none.

METHODS

Subjects

We enrolled 450 patients with Graves' disease (characterized by hyperthyroidism, diffuse goiter, and thyroid autoantibodies in serum) and mild ophthalmopathy or none. Mild ophthalmopathy was defined as proptosis of less than 22 mm, intermittent diplopia or none, an absence of optic neuropathy, and mild conjunctival and periorbital inflammation. Seven patients were lost to follow-up soon after enrollment, leaving 443 in the study cohort. Patients with severe ophthalmopathy requiring treatment with orbital radiotherapy and glucocorticoids, those with large goiters requiring thyroidectomy, and those with contraindications to glucocorticoid treatment were excluded before enrollment. The study was ap-

From the Istituto di Endocrinologia (L.B., C.M., E.B., L.M., M.L.T., E.D., G.B.-B., E.M., A.P.) and the Clinica Oculistica (M.N., M.P.B., A.L.), University of Pisa, and the Reparto di Epidemiologia e Biostatistica, Istituto di Fisiologia Clinica, National Research Council (G.R.) — all in Pisa, Italy. Address reprint requests to Dr. Bartalena at the Istituto di Endocrinologia, University of Pisa, Ospedale Cisanello, Via Paradisa, 3, 56122 Pisa, Italy.

proved by the institutional review board of the Institute of Endocrinology, and all patients gave their informed, written consent.

Treatment

All the patients were treated with methimazole for three to four months. They were then randomly assigned to receive radioiodine therapy, radioiodine therapy plus prednisone, or continued methimazole therapy. Methimazole was discontinued five days before the administration of radioiodine (given at a dose of 120 to 150 μCi [4.4 to 5.6 MBq] per gram of thyroid tissue). The patients in the radioiodine-prednisone group were initially given 0.4 to 0.5 mg of prednisone per kilogram of body weight starting two to three days after radioiodine therapy and continuing for one month; the dose was then tapered over a period of two months, and the drug was discontinued.⁶ Of the initial 450 patients, 315 (70 percent) had been given a diagnosis of hyperthyroidism and had previously been treated with methimazole, and 135 were euthyroid when referred to our center. The patients were seen and their thyroid function was checked within 1 month after radioiodine therapy and then every 1 to 2 months for 12 months. Hypothyroidism or persistent (i.e., uncontrolled) hyperthyroidism after radioiodine treatment was corrected within two to three weeks by the administration of thyroxine or methimazole, respectively. A second dose of radioiodine was administered to patients who had persistent hyperthyroidism at the end of follow-up. The methimazole-treated patients received the lowest dose of the drug that maintained euthyroidism.

Ocular Examinations

Ocular examinations were carried out every one to two months by a single examiner, who did not know which treatment was being administered to the patient. The examinations included evaluation of soft-tissue changes; measurements of proptosis (by Hertel exophthalmometer), lid width, and lagophthalmos; evaluation of eye-muscle function with the Hess chart; and determination of visual acuity. The activity of ophthalmopathy was scored by the method of Mourits et al.,⁷ which takes into consideration seven manifestations of disease (spontaneous retrobulbar pain, pain with eye movement, eyelid erythema, eyelid edema, conjunctival injection, chemosis, and swelling of the caruncle); one point is given for any manifestation, and the score may range from 0 (no activity) to 7 (very high activity). At each visit, the patients were asked to describe their eye disease as improved, unchanged, or worsened as compared with their last visit.

We defined the appearance, progression, or improvement of ophthalmopathy according to major and minor criteria. The major criteria were variations of 2 mm or more in exophthalmometric readings and lid width, the appearance or disappearance of diplopia (intermittent [i.e., present only occasionally], inconstant [i.e., present but not in primary gaze], constant [present in primary gaze]), variations of two points or more in the ophthalmopathy-activity score, and changes of $\frac{1}{10}$ or more in visual acuity. Minor criteria were variations in soft tissues or in the patient's assessment of his or her disease. The appearance, progression, or improvement of ophthalmopathy was defined as the appropriate change in at least two major and one minor criteria. The need for subsequent orbital radiotherapy and high-dose prednisone therapy for severe ophthalmopathy was determined by an overall evaluation that took into account the degree of inflammatory changes and related symptoms, the extent of proptosis and extraocular muscle dysfunction, any optic-nerve involvement, and the degree of interference with the patient's daily activities.

Evaluation of Thyroid Function

Thyroid function was assessed by measuring serum free thyroxine and free triiodothyronine (Lisophase kits, Laboratori Bouty, Sesto San Giovanni, Italy) and serum thyrotropin (Auto-Delfia Wallac, Gaithersburg, Md.). The normal ranges were as follows: free thyroxine, 0.6 to 1.8 ng per deciliter (8.4 to 23.2 pmol per liter); free triiodothyronine, 0.25 to 0.6 ng per deciliter (3.8 to

8.4 pmol per liter); and thyrotropin, 0.4 to 3.7 mU per liter. Serum thyrotropin-receptor antibody was measured by radioreceptor assay (Trak assay, Brahms Diagnostica, Berlin, Germany; normal value, <5 U per liter).

Statistical Analysis

Base-line values in the three groups were compared by one-way analysis of variance and the Kruskal-Wallis test for quantitative variables and the two-tailed Fisher's exact test for qualitative variables. Differences between pretreatment and post-treatment values for exophthalmometric readings, lid-width measurements, and ophthalmopathy-activity scores were compared by the two-tailed Student's t-test and the Wilcoxon test; differences in diplopia status (absent vs. present) in the groups were evaluated with the exact binomial test for paired data. Differences among or within treatment groups with respect to the progression of ophthalmopathy and thyroid status were evaluated with the two-tailed Fisher's exact test. Exact binomial 95 percent confidence intervals were calculated for the proportion of patients who had development, worsening, or improvement of ophthalmopathy. Kaplan-Meier survival curves were used to illustrate the pattern of occurrence of ophthalmopathy according to treatment group.

RESULTS

There were no significant differences in the base-line clinical and biochemical characteristics of the patients in the three treatment groups (Table 1). The proportions of patients with and without ophthalmopathy at base line were similar.

Among the 150 patients treated with radioiodine alone, ophthalmopathy developed or worsened in 23 (15 percent; 95 percent confidence interval, 10 to 22 percent) during the year after treatment (Fig. 1): 17 of the 72 patients with preexisting ophthalmopathy (24 percent; 95 percent confidence interval, 14 to 35 percent) and 6 of the 78 patients without ophthalmopathy (8 percent; 95 percent confidence interval, 3 to 16 percent; $P=0.01$). In all cases, the changes occurred within the first six months after radioiodine treatment (Fig. 2). The remaining 55 patients with preexisting ophthalmopathy and the remaining 72 patients with no ophthalmopathy at base line had no changes in their eyes (Fig. 1). The prevalence of smokers was greater among the patients in whom ophthalmopathy developed or worsened than among those who had no change (83 percent vs. 50 percent, $P<0.001$).

Among the 145 patients treated with radioiodine and prednisone, 50 of the 75 patients who had ophthalmopathy at base line (67 percent; 95 percent confidence interval, 55 to 77 percent) had regression of ophthalmopathy; the remaining 95 patients (25 with and 70 without ophthalmopathy at base line) had no change (Fig. 1). No patient in this group had worsening of ophthalmopathy. Among the 148 patients treated with methimazole, 3 of the 74 patients with preexisting ophthalmopathy (4 percent; 95 percent confidence interval, 1 to 11 percent) had improvement in the severity of their eye disease, and 4 patients (3 with and 1 without preexisting ophthalmopathy) had new or worsening ophthalmopathy (3 percent; 95 percent confidence interval, 1 to

TABLE 1. BASE-LINE CHARACTERISTICS OF THE THREE GROUPS OF PATIENTS WITH GRAVES' HYPERTHYROIDISM.*

CHARACTERISTIC	RADIOIODINE GROUP (N=150)	RADIOIODINE-PREDNISONE GROUP (N=145)	METHIMAZOLE GROUP (N=148)
Sex — M/F	29/121	28/117	28/120
Age — yr			
Mean	44	42	41
Range	16-85	15-69	17-77
Smoker — no. (%)	82 (55)	87 (60)	84 (57)
Range of duration of hyperthyroidism — mo	4-13	5-14	3-15
Mean thyroid volume — ml†	33	30	28
Ophthalmopathy			
Present	72	75	74
Absent	78	70	74
Proptosis — mm	17±2	17±1	17±1
Lid width — mm	11±2	11±2	11±1
Ophthalmopathy-activity score	1.1±1.1	1.2±1.2	1.0±1.0
Diplopia			
Absent	102	101	105
Intermittent	33	27	26
Inconstant	15	17	17
Constant	0	0	0
Serum free thyroxine — ng/dl	1.2±0.1	1.3±1.6	1.3±1.0
Serum free triiodothyronine — ng/dl	0.4±0.4	0.4±0.6	0.4±0.4
Serum thyrotropin — mU/liter	0.8±0.6	0.9±0.7	1.0±0.7
Serum thyrotropin-receptor antibody (U/liter)	49±56	46±71	51±59
Positive thyrotropin-receptor-antibody test — %	66	61	68
Dose of radioiodine — MBq‡	407±112	444±136	—
Persistent hyperthyroidism after radioiodine therapy — no. (%)	21 (14)	17 (12)	—
Development of permanent hypothyroidism — no. (%)	93 (62)	96 (66)	0

*Plus-minus values are means ±SD. The normal ranges for laboratory values are as follows: free thyroxine, 0.6 to 1.8 ng per deciliter (8.4 to 23.2 pmol per liter); free triiodothyronine, 0.2 to 0.6 ng per deciliter (3.8 to 8.4 pmol per liter); and thyrotropin, 0.4 to 3.7 mU per liter. Normal values for serum thyrotropin-receptor antibody are <5 U per liter. To convert values for serum free thyroxine to picomoles per liter, multiply by 1.29. To convert values for serum free triiodothyronine to picomoles per liter, multiply by 1.54. All P values for comparisons between groups were ≥0.68.

†Thyroid volume was measured by ultrasonography.

‡To convert values for radioiodine to microcuries, multiply by 37.3.

7 percent) (Fig. 1). The frequency of the development or progression of ophthalmopathy was significantly higher in the radioiodine group than in either the radioiodine-prednisone group or the methimazole group ($P < 0.001$ for both comparisons), but there was no significant difference between the latter two groups ($P = 0.12$). The frequency of improvement of ophthalmopathy was significantly higher in the radioiodine-prednisone group than in the other two groups ($P < 0.001$ for both comparisons).

Among the 23 patients in the radioiodine group in whom ophthalmopathy developed or worsened, the change was transient (i.e., it lasted for two to three months) in 15 (65 percent) and persistent in 8 (35 percent), 7 of whom had ophthalmopathy at base line. Overall, orbital radiotherapy and high-dose glucocorticoid therapy for new or worsened

ophthalmopathy were required by eight patients in the radioiodine group (5 percent; 95 percent confidence interval, 2 to 10 percent), one patient in the methimazole group (1 percent, 95 percent confidence interval, 0 to 4 percent), and none in the radioiodine-prednisone group. The percentages of patients in each group who were euthyroid, hyperthyroid, and hypothyroid at various times did not differ significantly, except that more patients in the methimazole group were euthyroid during the follow-up period ($P \leq 0.04$) (Table 2). There was no relation between thyroid status and the development or progression of ophthalmopathy.

The development or progression of ophthalmopathy in the 23 patients in the radioiodine group involved soft-tissue changes (palpebral edema in 21 patients, conjunctival hyperemia in 19, chemosis in 17,

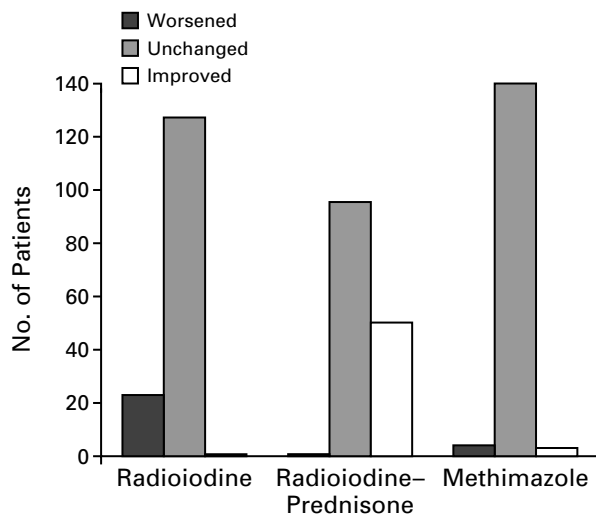
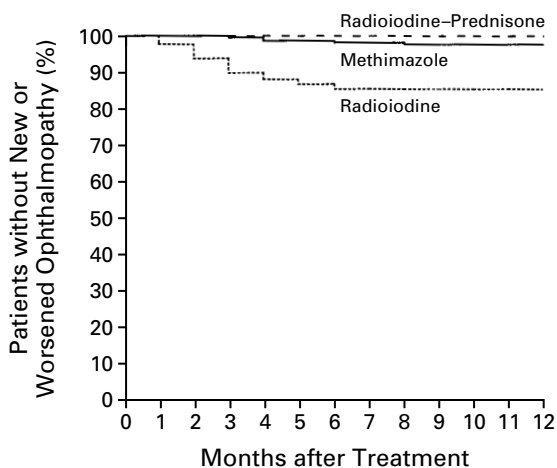


Figure 1. Changes in the Degree of Ophthalmopathy in Patients with Hyperthyroidism Who Were Treated with Radioiodine, Radioiodine and Prednisone, or Methimazole.

Patients in whom ophthalmopathy developed are included in the group with worsening. The determination of patients' status was based on an overall evaluation of ocular changes, variations in the ophthalmopathy-activity score, and the patients' own evaluation, as described in the Methods section.



TREATMENT GROUP	0	12	12
Radioiodine-prednisone	145	145	145
Methimazole	148	145	144
Radioiodine	150	127	127

Figure 2. Kaplan-Meier Plots of the Development or Progression of Ophthalmopathy in Patients with Hyperthyroidism Who Were Treated with Radioiodine, Radioiodine and Prednisone, or Methimazole.

The numbers at the bottom of the figure show the numbers of patients at risk (i.e., without new or worsened ophthalmopathy).

and edema of the caruncle in 19), an increase in proptosis in 18 patients, lid retraction in 17 patients, lagophthalmos in 10 patients, and diplopia in 14 patients (intermittent or inconstant in 6 and constant in 8). The mean ophthalmopathy-activity score and the degree of proptosis increased significantly in these 23 patients (Table 3). Soft-tissue changes were always associated with an increase in at least two major criteria for ophthalmopathy, and the patient's assessment confirmed the development or worsening of ophthalmopathy in all cases. No changes occurred in the remaining 127 patients in this group (Table 3).

The improvement of ophthalmopathy in 50 of the 75 patients in the radioiodine-prednisone group who had eye disease at base line involved soft-tissue changes (palpebral edema in 40, conjunctival hyperemia in 45, chemosis in 39, and edema of the caruncle in 34) and a decrease in proptosis (35 patients). Eye-muscle function improved in the 19 patients who had diplopia before treatment. The mean ophthalmopathy-activity score and the degree of proptosis decreased significantly in these 50 patients (Table 3), and all reported improvement. There were no side effects of prednisone treatment other than the appearance of cushingoid features, which disappeared after prednisone was discontinued.

DISCUSSION

Whether treatment of hyperthyroidism in patients with Graves' disease is associated with the development or progression of ophthalmopathy is the subject of much debate. In some retrospective studies, progression of preexisting eye disease was more common than its development after treatment of hyperthyroidism, although progression was not more common after any one of the three treatments — an antithyroid drug, radioiodine, or thyroidectomy — than after the others.^{3,8-12} In some other studies, including three prospective studies,^{6,13,14} radioiodine was associated with progression of ophthalmopathy.¹³⁻¹⁷ Although available comparative studies are limited, at least one prospective trial¹⁵ and two retrospective studies^{18,19} indicated that progression of ophthalmopathy was more common in patients treated with radioiodine than in those who received the other two treatments. The development or progression of ophthalmopathy after radioiodine therapy might be related to the release of thyroid antigens as a result of radiation injury and to subsequent enhancement of autoimmune responses directed toward antigens shared by the thyroid and the orbit.¹ The same mechanism has been postulated to explain the development of ophthalmopathy after irradiation of the neck for nonthyroidal disorders^{20,21} or after thyroid-destructive processes.²²

In this prospective, single-blind, controlled study, we found that radioiodine therapy for Graves' hyperthyroidism was followed by the development or,

TABLE 2. THYROID STATUS IN THE THREE GROUPS AT BASE LINE, DURING FOLLOW-UP, AND IN RELATION TO THE WORSENING OF OPHTHALMOPATHY.*

TIME AND STATUS	RADIOIODINE GROUP (N = 150)		RADIOIODINE- PREDNISONE GROUP (N = 145)		METHIMAZOLE GROUP (N = 148)	
	TOTAL	WITH WORSENING	TOTAL	WITH WORSENING	TOTAL	WITH WORSENING
number (percent)						
At base line						
Hyperthyroid	21 (14)	—	14 (10)	—	22 (15)	—
Euthyroid	128 (85)	—	130 (90)	—	125 (84)	—
Hypothyroid	1 (1)	—	1 (1)	—	1 (1)	—
Months 1-3						
Hyperthyroid	12 (8)	1 (8)	10 (7)	0	9 (6)	0
Euthyroid	115 (77)	13 (11)	109 (75)	0	132 (89)	1 (1)
Hypothyroid	23 (15)	2 (9)	26 (18)	0	7 (5)	0
Months 4-6						
Hyperthyroid	5 (3)	0	3 (2)	0	2 (1)	0
Euthyroid	117 (78)	6 (5)	109 (75)	0	144 (97)	2 (1)
Hypothyroid	28 (19)	1 (4)	33 (23)	0	2 (1)	0
Months 7-9						
Hyperthyroid	2 (1)	0	2 (1)	0	1 (1)	0
Euthyroid	126 (84)	0	123 (85)	0	143 (97)	1 (1)
Hypothyroid	22 (15)	0	20 (14)	0	4 (3)	0
Months 10-12						
Hyperthyroid	2 (1)	0	2 (1)	0	1 (1)	0
Euthyroid	128 (85)	0	125 (86)	0	145 (98)	0
Hypothyroid	20 (13)	0	18 (12)	0	2 (1)	0

*Worsening of ophthalmopathy refers to the development of ophthalmopathy in those without it at base line and the progression of eye disease in those with ophthalmopathy at base line. Hyperthyroidism was defined as a high serum free thyroxine or free triiodothyronine concentration and an undetectable serum thyrotropin concentration; hypothyroidism was defined as a low serum free thyroxine concentration and a high serum thyrotropin concentration. Patients who were not euthyroid at various times in the radioiodine group and radioiodine-prednisone group were given methimazole if they were hyperthyroid or thyroxine if they were hypothyroid; thus, at each time euthyroid patients include treated hypothyroid and hyperthyroid patients.

TABLE 3. OCULAR FINDINGS IN THE THREE GROUPS BEFORE TREATMENT AND ONE YEAR LATER.*

CHARACTERISTIC AND OUTCOME†	RADIOIODINE GROUP (N = 150)		RADIOIODINE- PREDNISONE GROUP (N = 145)		METHIMAZOLE GROUP (N = 148)	
	BEFORE TREATMENT	AT 12 MO	BEFORE TREATMENT	AT 12 MO	BEFORE TREATMENT	AT 12 MO
Proptosis (mm)						
Unchanged	17±2	17±2	17±2	17±1	17±1	17±1
Worse	17±2	19±1‡	—	—	17±2	19±2‡
Improved	—	—	17±1	15±1‡	18±1	16±1‡
Lid width (mm)						
Unchanged	11±2	11±2	11±1	11±1	11±1	10±1
Worse	11±2	14±1‡	—	—	10±2	13±2‡
Improved	—	—	11±2	9±2‡	12±1	9±1‡
Ophthalmopathy- activity score						
Unchanged	1±1	1±1	1±1	1±1	1±1	1±1
Worse	2±1	3±1‡	—	—	2±1	3±1‡
Improved	—	—	2±1	2±1‡	2±1	0‡
Diplopia§						
Unchanged	87, 29, 11, 0	87, 29, 11, 0	70, 17, 8, 0	70, 17, 8, 0	103, 25, 14, 0	103, 25, 14, 0
Worse	15, 4, 4, 0	1‡, 7, 7, 8	—	—	0, 0, 3, 1	0, 0, 3, 1
Improved	—	—	31, 10, 9, 0	50‡, 0, 0, 0	2, 1, 0, 0	3, 0, 0, 0

*Plus-minus values are means ±SD.

†“Worse” refers to either the development or the progression of ophthalmopathy.

‡P<0.001 for the comparison with the value before treatment.

§For diplopia, the numbers indicate in how many patients diplopia was absent, intermittent, inconstant, and constant, respectively.

more often, the progression of ophthalmopathy in patients treated with radioiodine alone, but not in those treated with radioiodine and prednisone; the patients treated with methimazole had no progression of eye disease. The worsening of eye disease was slight and transient in the majority of patients, but it persisted and ultimately required treatment with orbital radiotherapy and high-dose prednisone in a few. Of the three treatments, only the administration of prednisone after radioiodine therapy was associated with amelioration of preexisting eye disease during the one-year follow-up period, thus yielding more favorable results than those in the methimazole group.

How can the effects of radioiodine therapy on Graves' ophthalmopathy be explained? First, in many patients, the onset of ophthalmopathy, or its worsening, if it is already present, is slight and transient, and the condition is likely to be missed unless the patients are examined often. We examined our patients every one to two months not only to detect changes in their eyes but also to correct hypothyroidism promptly, because prompt amelioration of hypothyroidism reduces the likelihood that ophthalmopathy will progress after radioiodine therapy.²³ A second explanation might lie in the selection of patients; worsening of ophthalmopathy after radioiodine therapy does not occur in all patients, suggesting that other known risk factors (e.g., smoking^{24,25}) and unknown risk factors contribute to the development or progression of eye disease. In this regard, the varying duration of hyperthyroidism and ophthalmopathy in the different studies might also be a confounding variable.²⁶ Base-line serum thyroid hormone concentrations may be a risk factor, because in one study the development or worsening of ophthalmopathy was more frequent among patients who had higher serum free triiodothyronine concentrations before radioiodine therapy.¹³ The values in our patients did not vary, but all had been treated with methimazole before randomization.

Because antithyroid-drug treatment is not often followed by the development or progression of ophthalmopathy, it might be argued that patients with ophthalmopathy should be treated with such a drug, while waiting for hyperthyroidism and ophthalmopathy to subside spontaneously. However, antithyroid-drug treatment can be associated with unsatisfactory control of hyperthyroidism and, more important, hyperthyroidism can recur after the withdrawal of therapy.^{27,28} Persistent hyperthyroidism or its recurrence after the discontinuation of antithyroid-drug therapy could negatively affect the course of ophthalmopathy.¹⁶ Thus, we think that it is best to achieve permanent control of hyperthyroidism in patients with ophthalmopathy. Radioiodine accomplishes this well. Although, in the short term, it may have negative effects on eye disease, these are often transient and can be prevented by moderate doses of glucocorticoids.

Presented in abstract form at the 11th International Thyroid Congress, Toronto, September 10-15, 1995.

REFERENCES

- Burch HB, Wartofsky L. Graves' ophthalmopathy: current concepts regarding pathogenesis and management. *Endocr Rev* 1993;14:747-93.
- Prummel MF, Wiersinga WM, Mourits MP, Koornneef L, Berghout A, van der Gaag R. Effect of abnormal thyroid function on the severity of Graves' ophthalmopathy. *Arch Intern Med* 1990;150:1098-101.
- Sridama V, DeGroot LJ. Treatment of Graves' disease and the course of ophthalmopathy. *Am J Med* 1989;87:70-3.
- Marcocci C, Bartalena L, Bogazzi F, Bruno-Bossio G, Pinchera A. Relationship between Graves' ophthalmopathy and type of treatment of Graves' hyperthyroidism. *Thyroid* 1992;2:171-8.
- Winsa B, Rastad J, Akerstrom G, Johansson H, Westermark K, Karlsson FA. Retrospective evaluation of subtotal and total thyroidectomy in Graves' disease with and without endocrine ophthalmopathy. *Eur J Endocrinol* 1995;132:406-12.
- Bartalena L, Marcocci C, Bogazzi F, Panicucci M, Lepri A, Pinchera A. Use of corticosteroids to prevent progression of Graves' ophthalmopathy after radioiodine therapy for hyperthyroidism. *N Engl J Med* 1989;321:1349-52.
- Mourits MP, Koornneef L, Wiersinga WM, Prummel MF, Berghout A, van der Gaag R. Clinical criteria for the assessment of disease activity in Graves' ophthalmopathy: a novel approach. *Br J Ophthalmol* 1989;73:639-44.
- Gwinup G, Elias AN, Ascher MS. Effect on exophthalmos of various methods of treatment of Graves' disease. *JAMA* 1982;247:2135-8.
- Calissendorff BM, Soderstrom M, Alveryd A. Ophthalmopathy and hyperthyroidism: a comparison between patients receiving different antithyroid treatments. *Acta Ophthalmol (Copenh)* 1986;64:698-703.
- Vásquez-Chávez C, Nishimura Meguro E, Espinosa Said L, Delgado Falfari A, Sáinz de Viteri M. Influencia del tratamiento del hipertiroidismo en el curso del exoftalmos. *Rev Invest Clin* 1992;44:241-7.
- Fernandez Sanchez JR, Rosell Pradas J, Carazo Martinez O, et al. Graves' ophthalmopathy after subtotal thyroidectomy and radioiodine therapy. *Br J Surg* 1993;80:1134-6.
- Bartley GB, Fatourehchi V, Kadmas EF, et al. Chronology of Graves' ophthalmopathy in an incidence cohort. *Am J Ophthalmol* 1996;121:426-34.
- Tallstedt L, Lundell G, Tørring O, et al. Occurrence of ophthalmopathy after treatment for Graves' hyperthyroidism. *N Engl J Med* 1992;326:1733-8.
- Kung AWC, Yau CC, Cheng A. The incidence of ophthalmopathy after radioiodine therapy for Graves' disease: prognostic factors and the role of methimazole. *J Clin Endocrinol Metab* 1994;79:542-6.
- Vestergaard H, Laurberg P. Radioiodine and aggravation of Graves' ophthalmopathy. *Lancet* 1989;2:47.
- Karlsson FA, Westermark K, Dahlberg PA, Jansson R, Enoksson P. Ophthalmopathy and thyroid stimulation. *Lancet* 1989;2:691.
- Barth A, Probst P, Burgi H. Identification of a subgroup of Graves' disease patients at higher risk for severe ophthalmopathy after radioiodine. *J Endocrinol Invest* 1991;14:209-12.
- Hetzl BS, Mason EK, Wang HK. Studies of serum long-acting thyroid stimulator (LATS) in relation to exophthalmos after therapy for thyrotoxicosis. *Australas Ann Med* 1968;17:307-11.
- Aron-Rosa D, Pérez R, Abitbol Y. Malignant exophthalmos after iodine-131 treatment. *Mod Probl Ophthalmol* 1973;14:432-4.
- Wasnich RD, Grumet FC, Payne RO, Kriss JP. Graves' ophthalmopathy following external neck irradiation for nonthyroidal neoplastic disease. *J Clin Endocrinol Metab* 1973;37:703-13.
- Jackson R, Rosenberg C, Kleinmann R, Vagenakis AG, Braverman LE. Ophthalmopathy after neck irradiation therapy for Hodgkin's disease. *Cancer Treat Rep* 1979;63:1393-5.
- Bartalena L, Bogazzi F, Pecori F, Martino E. Graves' disease occurring after subacute thyroiditis: report of a case and review of the literature. *Thyroid* 1996;6:345-8.
- Tallstedt L, Lundell G, Blomgren H, Bring J. Does early administration of thyroxine reduce the development of Graves' ophthalmopathy after radioiodine treatment? *Eur J Endocrinol* 1994;130:494-7.
- Bartalena L, Martino E, Marcocci C, et al. More on smoking habits and Graves' ophthalmopathy. *J Endocrinol Invest* 1989;12:733-7.
- Bartalena L, Bogazzi F, Tanda ML, Manetti L, Dell'Unto E, Martino E. Cigarette smoking and the thyroid. *Eur J Endocrinol* 1995;133:507-12.
- Wiersinga WM, Prummel MF. Retrobulbar radiation in Graves' ophthalmopathy. *J Clin Endocrinol Metab* 1995;80:345-7.
- Marcocci C, Giancchetti D, Masini I, et al. A reappraisal of the role of methimazole and other factors on the efficacy and outcome of radioiodine therapy of Graves' hyperthyroidism. *J Endocrinol Invest* 1990;13:513-20.
- Vitti P, Rago T, Chiovato L, et al. Clinical features of patients with Graves' disease undergoing remission after antithyroid drug treatment. *Thyroid* 1997;7:369-75.